



PATIENT

Emma Moon

PRESENTING CLINICAL SIGNS

History: Irregular rhythm noted on exam. Weight Loss. Anorexia. Pleural effusion noted. Thoracocentesis was performed to remove 1250ml fluid.

SPECIES

Canine

ELECTROCARDIOGRAPHIC FINDINGS *Note: Single lead ECGs are evaluated as a rhythm strip. Morphology/MEA cannot be definitively commented on.

A single lead ECG is available; 50mm/s, 0mm/mV. The average heart rate is 170bpm (range 130-200bpm). P waves are not apparent with an irregular rhythm, most consistent with atrial fibrillation. A single VPC is noted.

BREED

Great Dane

ECG diagnosis: Atrial fibrillation with a single VPC.

SEX

Female Spayed

ECHOCARDIOGRAM FINDINGS

2D, m-mode, color flow and doppler imaging is available. Severe left ventricular dilation with diminished systolic function. Decreased LV wall thickness and increased sphericity. The mitral valve appears mildly thickened with no obvious prolapse into the left atrial lumen. Moderate central mitral regurgitation. Decreased MR velocity. The tricuspid valve appears normal. Mild right atrial and ventricular dilation. Mild to moderate tricuspid regurgitation. Normal velocity. The aortic valve is normal in morphology and mobility. No aortic insufficiency. Normal pulmonic valve. No aortic or pulmonic insufficiency seen. Normal LVOT/RVOT velocities. Scant pericardial effusion noted. Large volume pleural effusion. Abdominal effusion seen on subcostal views. No obvious cardiac tumors.

AGE

9 years

WEIGHT

139lbs

CARDIAC CHART

INTERPRETED BY

Maggie Machen Lamy,
DVM, DACVIM
(Cardiology)

CANINE CARDIAC PARAMETERS	MR VMAX (m/s)	TR VMAX (m/s)	LA/AO (Boon method)	LA/AO (Heart Base; Swe)	FS (%)	EF (%)	EPSS (cm)
NORMAL PARAMETER	4.5-5.5	<2.7	1.3	<1.6	28-40	40-100	<0.6
PATIENT	4.3	2.6	2.0	2.5	15	28	2.0
CANINE CARDIAC PARAMETERS	HR (BPM)	AV VMAX (m/s)	PV MAX (m/s)	BODY WEIGHT (kg)	LA 2D short axis Base view (cm)	LVIDd Avg; 2D and m-mode short axis (cm)	LVIDs Avg; 2D and m-mode short axis (cm)
NORMAL PARAMETER	50-100	0.7-1.7	0.7-1.6	BELOW	BELOW	BELOW	BELOW
PATIENT	NM	0.8	0.5	63.0	7.0	8.9	7.6
*Normal chamber parameters expressed as a mean value (SD)				3	1.27 (5.3)	2.46 (2.46)	1.36 (5.5)
BODY WEIGHT DEPENDENT PARAMETERS				5	1.40 (4.5)	2.74 (5.2)	1.60 (4.7)
*Note: All measurements based upon multi-modal images and methods. An average value is reported.				10	1.50 (3.8)	3.27 (3.5)	2.06 (3.1)
				15	1.83 (2.0)	3.71 (2.4)	2.43 (2.1)
				20	2.02 (1.9)	4.14 (2.2)	2.80 (2.0)
				25	2.18 (2.4)	4.48 (2.9)	3.10 (2.5)
				30	2.33 (3.3)	4.83 (3.9)	3.39 (3.4)
				35	2.48 (4.3)	5.17 (5.0)	3.69 (4.5)
				40	2.62 (5.2)	5.48 (6.1)	3.96 (5.4)
				50	2.88 (7.1)	6.07 (8.3)	4.46 (7.4)

Adapted from June Boon, Veterinary Echocardiography, 1998
Rishniw M and Hollis NE, J Vet Intern Med 2000; 14:429-435
Hansson et al, Vet Rad and Ultrasound 2002
Bonagura et al. Echocardiography: principles of interpretation, Vet Clin North Am 15:1177, 1995

IMAGING PERFORMED BY

S. Doverspike, DVM

HOSPITAL NAME

Franklin Animal Clinic Inc

REFERRING VET

Dr. Doverspike

INVOICE

32388

DATE

8/16/23



PATIENT

Emma Moon

SPECIES

Canine

BREED

Great Dane

SEX

Female Spayed

AGE

9 years

WEIGHT

139lbs

INTERPRETED BY

Maggie Machen Lamy,
DVM, DACVIM
(Cardiology)

IMAGING PERFORMED BY

S. Doverspike, DVM

HOSPITAL NAME

Franklin Animal Clinic
Inc

REFERRING VET

Dr. Doverspike

INVOICE

32388

DATE

8/16/23

INTERPRETATION OF THE FINDINGS & FURTHER RECOMMENDATIONS

Unfortunately, this patient has significant cardiomyopathy and systolic dysfunction. This is causing dilation and overload of all 4 chambers resulting in insufficiency of the mitral and tricuspid valves. Tricavitary effusion and a reported cough are certainly consistent with biventricular CHF.

Systolic failure can be primary in nature (DCM) or secondary to taurine deficiency, myocarditis, tachycardia-induced cardiomyopathy, or infiltrative disease such as lymphoma. In a senior giant breed dog, primary disease is certainly possible; however, consider testing for primary causes that may be treatable. A troponin (cTnI) level can be submitted to further investigate infiltrative/inflammatory contribution (myocarditis). Additionally, a taurine level may be helpful (screen for malabsorption issue) with avoidance of grain free, exotic ingredient or boutique brand options going forward.

Regardless of cause, prognosis is guarded to poor at this stage in the disease process, with an average survival time of <6 months. Patient will always be at risk for recurrent CHF, development of malignant arrhythmias and/or sudden death in the future. The only treatable cause of systolic failure is taurine deficiency, which is uncommon on commercially formulated dog foods (albeit renewed with the recent correlation to grain free diets). If a taurine level is declined, it is also reasonable to simply supplement with taurine on the off chance of a malabsorption issue.

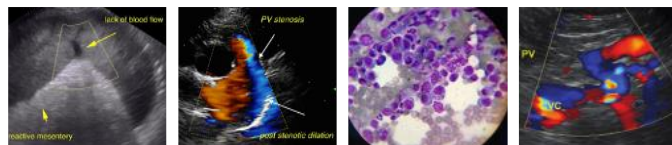
As a complicating factor, the patient has also developed rapid atrial fibrillation (AF) secondary to atrial dilation. Development of the arrhythmia puts the patient at high risk for acute decompensation and development of right-sided congestion (ascites in this case). AF is characterized by disorganized contractions of the atria leading to an irregular heart rhythm. The irregular heart rhythm rarely causes clinical signs in dogs. However, atrial fibrillation also usually causes an increase in the heart rate, and this can lead to clinical signs and CHF as we see in this patient. Once a patient is in AF, this will likely never convert back to sinus rhythm, however they typically do well with simply rate control. **It is somewhat unusual that the patient still has brief pauses resulting in a lower average heart rate. Regardless, rate control is recommended; however, we must be careful not to drop the resting rate too low.**

Monitoring of sleeping respiratory rates will be paramount to screen for recurrent congestive heart failure at home in the future. Cough suppression to improve QOL can also be considered once diuretics are on board for any residual mechanical cough in the face of normal sleeping respiratory rates.

Monitor for development of a cough, labored breathing, exercise intolerance or collapse episodes in the future. Monitoring of sleeping breathing rates at home is recommended to screen for progression to CHF. Omega fatty acid supplementation (1000mg once to twice daily) and mild salt restriction may be of some long-term benefit.

PLAN:

If the patient appears unstable, recommend referral for 24-hour monitoring/supportive care and IV rate control/diuretics. Recommend the following oral medications: Pimobendan 0.3mg/kg PO q12h, Lasix 1-2mg/kg PO q12h; Spironolactone 1-2mg/kg PO q12h; Diltiazem 1mg/kg PO q8h, up titrate to affect. Institute taurine supplement 1000-2000mg PO q12h. Consider diet history, taurine level, cTnI, etc. as discussed.



PATIENT

Emma Moon

Recheck BP, heart rate/ECG and renal values in 5-7 days. If BP >130mmHg and patient is feeling well, institute Benazepril at that time (0.5mg/kg PO q12h). Target HR is 140-160bpm in hospital/stressed. Up-titrate diltiazem to effect. If difficult to control, can also consider digoxin (0.005mg/kg PO q12h with close monitoring of blood dig levels) due to synergistic effect with diltiazem.

SPECIES

Canine

BREED

Great Dane

Monitor renal values/BP/HR every 3-4 months lifelong.

A recheck echocardiogram is recommended in 4-6 months to screen for progression.

SEX

Female Spayed

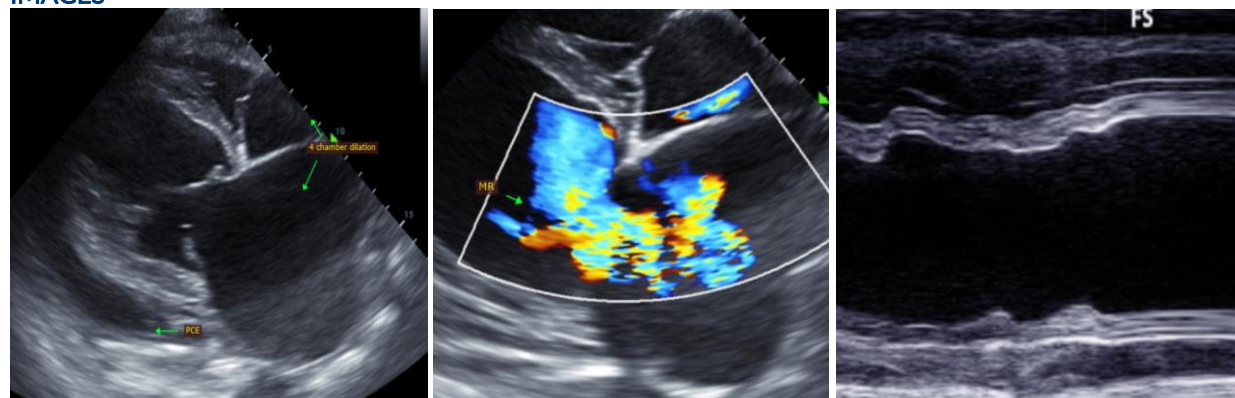
AGE

9 years

WEIGHT

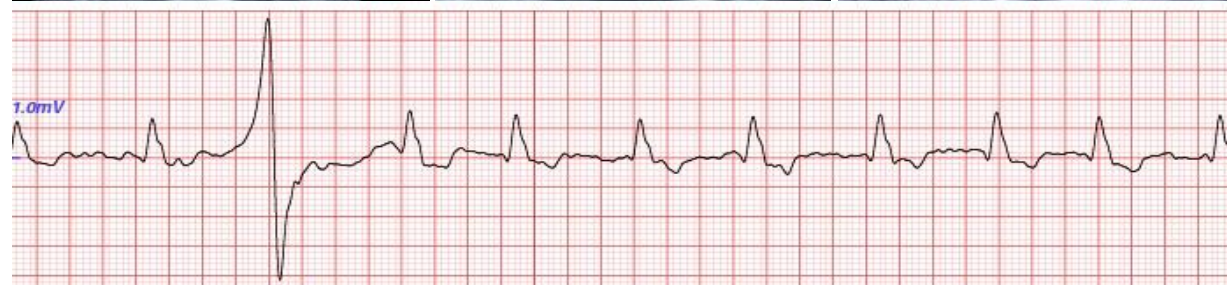139lbs

IMAGES



INTERPRETED BY

Maggie Machen Lamy,
DVM, DACVIM
(Cardiology)



IMAGING PERFORMED BY

S. Doverspike, DVM

HOSPITAL NAME

Franklin Animal Clinic
Inc

The information and recommendations provided are based on the images presented by the referring veterinarian. No evaluation can be communicated regarding pathology that was not visible in the image/video clips provided.

REFERRING VET

Dr. Doverspike

Thank you for this referral. This report was generated using transcription software, and minor dictation errors may be present. If the clinical or image interpretation does not parallel your findings or if I can be of any further assistance, please contact me.

INVOICE

32388

Maggie Machen Lamy, DVM
Diplomate of the American College of Veterinary Internal Medicine (Cardiology)
info@sonopath.com

DATE

8/16/23